



Neoatherosclerosis: mirage of an ancient illness or genuine disease condition?

Kazuyuki Yahagi, Fumiyuki Otsuka, Renu Virmani, and Michael Joner*

CVPath Institute, Gaithersburg, MD, USA

This editorial refers to ‘The association between in-stent neoatherosclerosis and native coronary artery disease progression: a long-term angiographic and optical coherence tomography cohort study’, by M. Taniwaki et al., on page doi:10.1093/eurheartj/ehv227.

In-stent neoatherosclerosis has become the darling of the interventional cardiology community and is blamed for most stent thrombosis (ST) occurring late after drug-eluting stent (DES) implantation. Neoatherosclerosis accounted for only 33% of late and very late ST at autopsy following implantation of first-generation DES.¹ However, the clinical prevalence of neoatherosclerosis and its percentage of cases presenting with late and very late ST remains unknown.

In the current issue of the journal, Taniwaki et al. propose a significant and biologically relevant association between the presence of in-stent neoatherosclerosis and the progression of native atherosclerosis in a cohort of 88 patients included in the SIRTAX LATE OCT study 5 years following DES implantation.² The primary clinical endpoint of this study was the occurrence of any non-target lesion revascularization (non-TLR), not accounting for any revascularization procedures within the target lesion, i.e. DES segment. The authors report a frequency of neoatherosclerosis of 15.9% in lesions treated with either paclitaxel-eluting (PES) or sirolimus-eluting stents (SES), which was significantly greater in PES than SES (22.5% vs. 4.9%, $P = 0.009$). Neoatherosclerosis was defined as fibroatheroma or fibrocalcific plaque within the neointimal tissue based on the standard optical coherence tomography (OCT) definition of attenuated lipid-rich and calcified plaque.³ The authors report plaque progression in both groups, i.e. with or without neoatherosclerosis (change of percentage stenosis diameter: 6.0% in those with vs. 4.3% in those without neoatherosclerosis), with a highly significant difference in the rates of non-TLR up to 5 years in those with neoatherosclerosis vs. those without (79% vs. 45%, $P = 0.006$).

Most of our knowledge about neoatherosclerosis has been acquired from histopathology and small-sized observational intravascular imaging studies, which reported an acceleration of neoatherosclerosis formation in DES relative to bare metal stents (BMS) of

similar duration.⁴ In-stent neoatherosclerosis is histologically characterized by an accumulation of lipid-laden foamy macrophages with or without necrotic core formation and/or calcification within the neointima.⁴ While histopathology studies play a key role in identifying acute and late stent failure modes, one important limitation refers to their retrospective nature depicting a single snap-shot of human disease conditions and selection bias. In keeping with this limitation, the clinical study by Taniwaki et al.² provides valuable insights into the prospective evaluation of neoatherosclerosis and its effect on systemic progression of atherosclerosis in native non-stented atherosclerotic arteries up to 5 years after DES implantation. In fact, the current study represents the longest invasive imaging follow-up surveillance of DES-treated patients with focus on neoatherosclerosis formation to date. Nevertheless, important pathophysiological and epidemiological questions remain unanswered.

We have known for a long time that treating culprit plaques does not prevent disease progression elsewhere, which was shown in the NHLBI Dynamic registry of consecutive patients undergoing percutaneous coronary intervention (PCI) at multiple centres between 1997 and 1999. Of 3747 PCI patients, 216 (5.8%) required symptom-driven non-TLR at 1 year.⁵ Fifty-nine per cent presented with new unstable angina, and 9.3% presented with non-fatal myocardial infarction. The mean stenosis of the progressed lesions was $41.8 \pm 20.8\%$ at the initial angiogram and $83.9 \pm 13.9\%$ at the time of the second angiogram, with a mean increase in stenosis severity of $42.1 \pm 21.9\%$.⁵ Utilizing the same registry, the outcome of three sets of patient cohorts enrolled in 1999, 2004, and 2006 and followed out to 5 years was reported.⁶ The key finding of this study was that despite a greater number of co-morbidities and severity in coronary artery disease manifestation over time, the rate of death, myocardial infarction, or repeat PCI at 5 year follow-up was not different, except for coronary artery bypass grafting, which was less frequently performed.⁶ This study is yet another good example of the failure of secondary prevention measures following percutaneous revascularization procedures and suggests our understanding of how to optimize secondary prevention may still be limited. The dilemma of failure to implement secondary prevention following revascularization was once more exemplified in the PROSPECT trial,⁷ the only study with appropriate power and design to investigate the

The opinions expressed in this article are not necessarily those of the Editors of the *European Heart Journal* or of the European Society of Cardiology.

* Corresponding author. CVPath Institute, Inc., 19 Firstfield Road, Gaithersburg, MD 20878, USA. Tel: +1 301 208 3570, Fax: +1 301 208 3745, Email: mjoner@cvpath.org

Published on behalf of the European Society of Cardiology. All rights reserved. © The Author 2015. For permissions please email: journals.permissions@oup.com.

conditional fate of culprit and non-culprit atherosclerotic plaques over 3 years of follow-up. In this study, major adverse cardiac events were equally attributable to non-culprit and culprit lesions, supporting the significance of secondary prevention to ameliorate disease progression in our patients. In light of this clinical need, the study by Taniwaki *et al.* suggests the implementation of more intense risk modification in patients diagnosed with neoatherosclerosis by OCT. However, it is also conceivable that patients undergoing invasive imaging procedures already represent a selected subgroup at much higher risk compared with asymptomatic patients not participating in clinical trials. Therefore, it remains unclear from the study by Taniwaki *et al.* if the observed frequency of neoatherosclerosis is representative of contemporary clinical practice or rather reflects an incidental finding of a selected group of patients undergoing invasive surveillance imaging.

In an invasive OCT study, Kang *et al.*⁸ focused selectively on patients presenting with DES restenosis and reported a frequency of 90% for lipid-containing neointima in 50 patients presenting with stable ($n = 30$) or unstable angina ($n = 20$). Thin-cap fibroatheroma-containing neointima was diagnosed in 26 lesions (52%) and in-stent neointimal rupture was observed in at least 29 lesions

(58%). In keeping with the above concern, the study by Kang *et al.* demonstrates how the prevalence of neoatherosclerosis becomes exaggerated when selected patient groups undergo invasive imaging protocols. On the other hand, the same study also supports the notion that there seems to be a clinical association between the occurrence of DES restenosis and neoatherosclerosis. In a more recent study, Lee *et al.*⁹ examined the frequency of neoatherosclerosis between first- and second-generation DES using intravascular imaging of 212 patients with $>50\%$ cross-sectional narrowing by OCT. They found a strikingly higher prevalence of neoatherosclerosis in first-generation compared with second-generation DES (45.5 vs. 10.8%, $P < 0.001$) in their crude analysis of consecutive patients. However, just like in the autopsy study, the data are skewed towards a much longer duration of first-generation DES as compared with their second-generation counterparts. Therefore, it is inappropriate to expect a lower prevalence of neoatherosclerosis even in second-generation DES in the longer term. These studies not only highlight the importance of patient selection but also determine the impact of neoatherosclerosis definition by OCT. While previous studies referred to neoatherosclerosis in the presence of any lipid-laden neointima (with or without calcification), the current

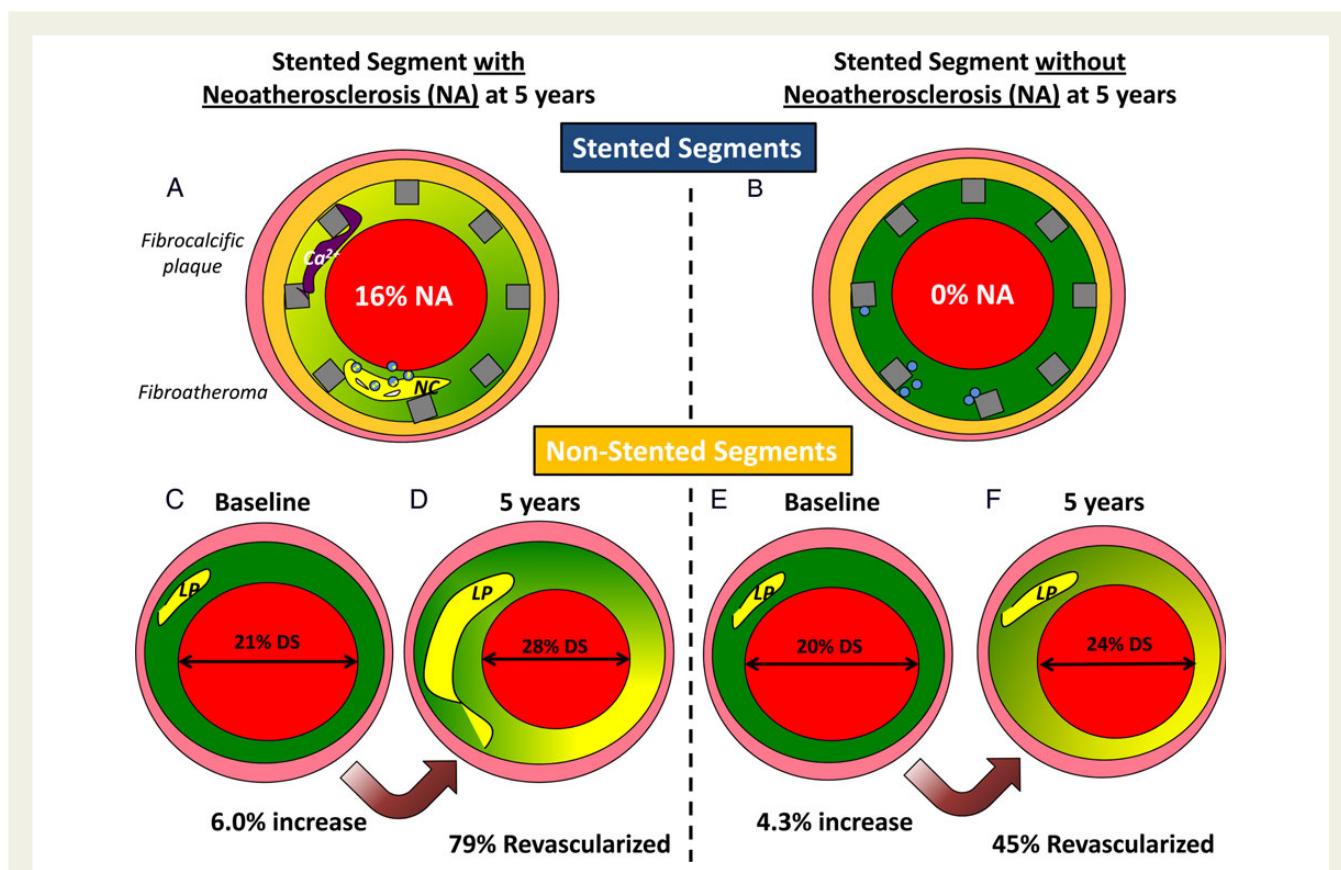


Figure 1 Comparison of plaque progression of non-target lesions in patients with neoatherosclerosis (NA) and in those without NA. (A and B) In-stent neoatherosclerosis (NA). Note NA was observed in 16% of lesions following DES implantation. (C and D) Non-stented segment of patients with NA showed greater luminal narrowing with significant plaque progression at 5 years. The change of percentage in stenosis diameter was 6.0%. (E and F) Non-stented segment of patients without NA showed similar luminal narrowing with mild plaque progression (percentage change in stenosis diameter was 4.3%) at 5 years. Non-target lesion revascularization was more frequently observed in patients with NA than in those without (79% vs 45%). Ca²⁺, calcium, DS, diameter stenosis; NC, necrotic core; LP, lipid pool.

study proposed a more stringent definition of neoatherosclerosis by requiring the obligatory presence of a more advanced stage of neoatherosclerosis, i.e. the presence of a necrotic core and/or fibrocalcific plaque. The current study probably also underdiagnosed the presence of neoatherosclerosis by selecting patients only presenting with event-free survival at 5 years after DES implantation. In a previous study by Räber *et al.*, the incidence of any TLR between 1 and 5 years and late/very late ST was 9.3% and 2.9%, respectively,¹⁰ which may have been caused by neoatherosclerosis. In other words, patients prone to a more rapid progression of atherosclerosis in native or stented coronary arteries have been excluded in the current study, which might also help explain why risk factors were similar between the patients with neoatherosclerosis and those without.

The key message from the current study certainly pertains to the association of native atherosclerosis progression and the presence of in-stent neoatherosclerosis in patients receiving first-generation DES (Figure 1). While this association seems to be intuitive, it also implies similarity in the aetiology and pathophysiology of atherosclerotic plaque formation in naive and stented coronary arteries. From our experience, however, there seems to be an important distinguishing feature differentiating between the two diseases. While pathological intimal thickening (PIT) with lipid pool is regarded as one of the earliest progressive atherosclerotic plaque types in native coronary arteries, early neoatherosclerotic plaque formation is commonly observed as foamy macrophage infiltration within the superficial neointimal tissue or peri-strut regions, which has not been addressed in the current study.

In summary, there seems to be an important association between the progression of atherosclerosis within naive and stented coronary arteries, which not only highlights the importance of dedicated studies to advance our understanding of this novel disease manifestation but also raises concern that effective implementation of secondary prevention measures has not yet been achieved.

Conflict of interest: F.O. has received speaking honorarium from Abbott Vascular, Bayer, Merck, and Terumo Corporation. R.V. receives research support from Abbott Vascular, BioSensors International, Biotronik, Boston Scientific, Medtronic, MicroPort Medical, OrbusNeich Medical, SINO Medical Technology, and Terumo Corporation; has speaking engagements with Merck; receives honoraria from Abbott Vascular, Boston Scientific, Lutonix, Medtronic, and Terumo Corporation; and is a consultant for 480 Biomedical, Abbott Vascular, Medtronic, and W.L. Gore. M.J. is a consultant for Biotronik and Cardionovum, and has received

speaking honorarium from Abbott Vascular, Biotronik, Medtronic, and St. Jude. K.Y. reports no conflicts of interest.

References

- Otsuka F, Sakakura K, Yahagi K, Sanchez OD, Kutys R, Ladich E, Fowler DR, Kolodgie FD, Davis HR, Joner M, Virmani R. TCT-655 contribution of in-stent neoatherosclerosis to late stent failure following bare metal and 1st- and 2nd-generation drug-eluting stent placement: an autopsy study. *J Am Coll Cardiol* 2014;**64**(11_S).
- Taniwaki M, Windecker S, Zaugg S, Stefanini GG, Baumgartner S, Zanchin T, Wenaweser P, Meier B, Juni P, Räber L. The association between in-stent neoatherosclerosis and native coronary artery disease progression: a long-term angiographic and optical coherence tomography cohort study. *Eur Heart J* 2015;doi:10.1093/eurheartj/ehv227.
- Tearney GJ, Regar E, Akasaka T, Adriaenssens T, Barlis P, Bezerra HG, Bouma B, Bruining N, Cho JM, Chowdhary S, Costa MA, de Silva R, Dijkstra J, Di Mario C, Dudek D, Falk E, Feldman MD, Fitzgerald P, Garcia-Garcia HM, Gonzalo N, Granada JF, Guagliumi G, Holm NR, Honda Y, Ikeno F, Kawasaki M, Kochman J, Koltowski L, Kubo T, Kume T, Kyono H, Lam CC, Lamouche G, Lee DP, Leon MB, Maehara A, Manfrini O, Mintz GS, Mizuno K, Morel MA, Nadkarni S, Okura H, Otake H, Pietrasik A, Prati F, Raber L, Radu MD, Rieber J, Riga M, Rollins A, Rosenberg M, Sirbu V, Serruys PW, Shimada K, Shinke T, Shite J, Siegel E, Sonoda S, Suter M, Takarada S, Tanaka A, Terashima M, Thim T, Uemura S, Ughi GJ, van Beusekom HM, van der Steen AF, van Es GA, van Soest G, Virmani R, Waxman S, Weissman NJ, Weisz G. Consensus standards for acquisition, measurement, and reporting of intravascular optical coherence tomography studies: a report from the International Working Group for Intravascular Optical Coherence Tomography Standardization and Validation. *J Am Coll Cardiol* 2012;**59**:1058–1072.
- Nakazawa G, Otsuka F, Nakano M, Vorpahl M, Yazdani SK, Ladich E, Kolodgie FD, Finn AV, Virmani R. The pathology of neoatherosclerosis in human coronary implants bare-metal and drug-eluting stents. *J Am Coll Cardiol* 2011;**57**:1314–1322.
- Glaser R, Selzer F, Faxon DP, Laskey WK, Cohen HA, Slater J, Detre KM, Wilensky RL. Clinical progression of incidental, asymptomatic lesions discovered during culprit vessel coronary intervention. *Circulation* 2005;**111**:143–149.
- Bortnick AE, Epps KC, Selzer F, Anwaruddin S, Marroquin OC, Srinivas V, Holper EM, Wilensky RL. Five-year follow-up of patients treated for coronary artery disease in the face of an increasing burden of co-morbidity and disease complexity (from the NHLBI Dynamic Registry). *Am J Cardiol* 2014;**113**:573–579.
- Stone GW, Maehara A, Lansky AJ, de Bruyne B, Cristea E, Mintz GS, Mehran R, McPherson J, Farhat N, Marso SP, Parise H, Templin B, White R, Zhang Z, Serruys PW. A prospective natural-history study of coronary atherosclerosis. *N Engl J Med* 2011;**364**:226–235.
- Kang SJ, Mintz GS, Akasaka T, Park DW, Lee JY, Kim WJ, Lee SW, Kim YH, Whan Lee C, Park SW, Park SJ. Optical coherence tomographic analysis of in-stent neoatherosclerosis after drug-eluting stent implantation. *Circulation* 2011;**123**:2954–2963.
- Lee SY, Hur SH, Lee SG, Kim SW, Shin DH, Kim JS, Kim BK, Ko YG, Choi D, Jang Y, Hong MK. Optical coherence tomographic observation of in-stent neoatherosclerosis in lesions with more than 50% neointimal area stenosis after second-generation drug-eluting stent implantation. *Circ Cardiovasc Interv* 2015;**8**:e001878.
- Raber L, Wohlwend L, Wigger M, Togni M, Wandel S, Wenaweser P, Cook S, Moschovitis A, Vogel R, Kalesan B, Seiler C, Eberli F, Luscher TF, Meier B, Juni P, Windecker S. Five-year clinical and angiographic outcomes of a randomized comparison of sirolimus-eluting and paclitaxel-eluting stents: results of the Sirolimus-Eluting Versus Paclitaxel-Eluting Stents for Coronary Revascularization LATE trial. *Circulation* 2011;**123**:2819–2828.